

Research Article

Separation of Fetal Hiccupping from Non-reactive FHR in Fetal Monitoring

Kazuo Maeda*

¹Department of Obstetrics and Gynecology, Tottori University School of Medicine, Japan

***Corresponding author:** Kazuo Maeda, MD, Ph.D, Honorary professor, Department of Obstetrics and Gynecology, Tottori University School of Medicine, 3-125 Nadamachi, Yonago, Tottoriken, 683-0835, Japan, Fax: 81-859-22-6856; E-mail: Maedak@mocha.ocn.ne.jp

Received: March 05, 2018; **Accepted:** April 23, 2018; **Published:** April 28, 2018

Copyright: ©2018 Kazuo Maeda. This is an open access article distributed under the Creative Commons Attribution License, which permits unrestricted use, distribution, and reproduction in any medium, provided the original work is properly cited.

Abstract

As fetal hiccupping movements accompanied no fetal heart rate (FHR) acceleration in actocardiogram, in spite of normal fetus without fetal hypoxia, the fetal hiccupping should be separated from the non-reactive FHR change, by no formation of movement burst, very regular repetition of sharp spikes and real-time B-mode ultrasound image.

Keywords: actocardiogram, FHR, fetal hiccupping, non-reactive FHR, FHR acceleration, electronic simulation

Introduction

The FHR acceleration is a sign of fetal well-being (Figure 1), of which loss, that is non-reactive FHR, is an early sign of hypoxic suppression of fetal brain (Figure 2), while there is no FHR acceleration in the continuous fetal hiccupping recorded by the actocardiogram [1], despite there was no hypoxic change, thus, the fetal movement in fetal hiccupping was studied comparing it to the case of the loss of acceleration and real-time ultrasonic B-mode image of fetal hiccupping.

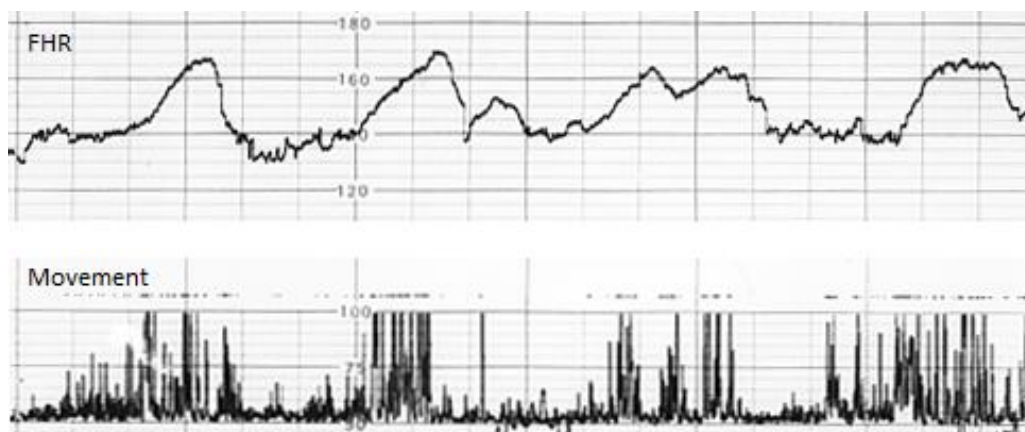


Figure 1: Normal fetal active state in actocardiogram, where transient FHR accelerations are synchronized with fetal movement groups (bursts).

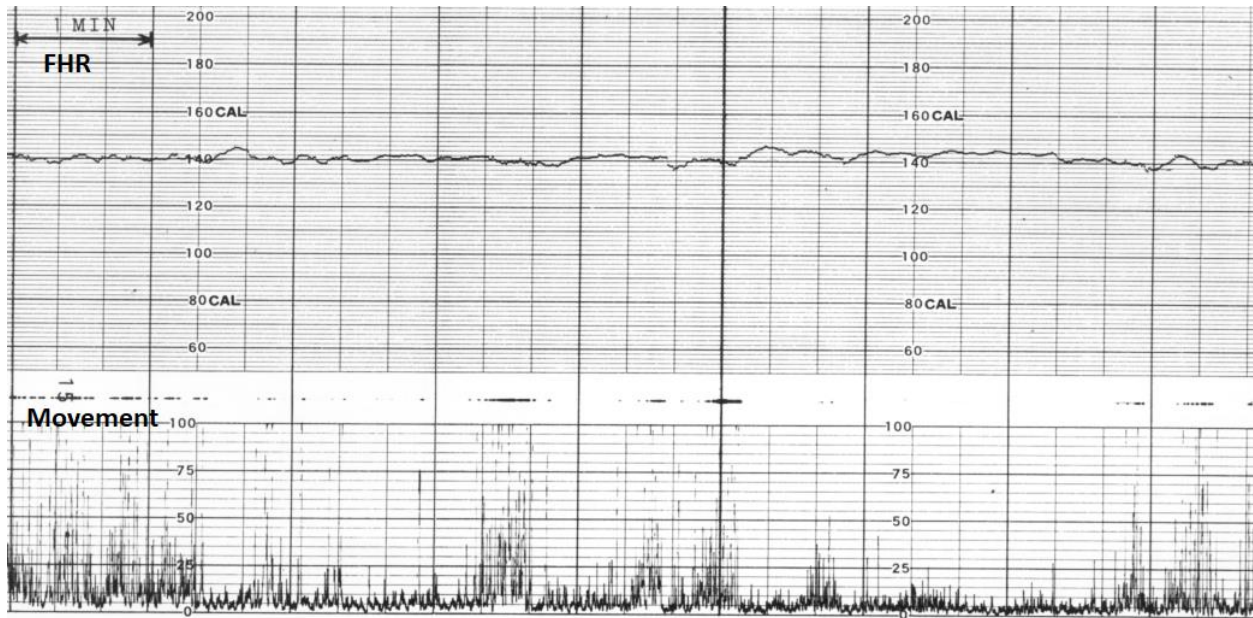


Figure 2: A non-reactive FHR in early stage of hypoxia, where FHR acceleration is lost against triangular fetal movement.

Methods

FHR accelerations are triangular transient elevation of heart rate synchronized with fetal movement bursts (Figure 1), while fetal hiccupping movement, which is local convulsive fetal diaphragmatic motion accompanying fetal body movement without central neurological control, and it appears regularly with 2 sec intervals, namely it is 0.5 Hz periodic phenomena. The interval is different from fetal breathing, i.e. fetal respiratory action appears once in one second, thus the respiration frequency is 1 Hz. Also, fetal hiccupping repeats for 10 or more minutes and able to appear twice in day time, of which start, and closure are sudden. Normal active fetal brain responds grouped fetal movements (movement burst) associating FHR acceleration, forming a transient tachycardia, which is the sign of healthy fetal brain, while the brain, damaged by hypoxia, does not respond fetal movement burst, and the acceleration is lost against fetal movement burst in early state of fetal hypoxia, thus, the loss of FHR acceleration is a sign of early hypoxic fetal brain suppression. However, hiccupping movements develop no movement burst, thus, fetal hiccupping motion does not accompany fetal acceleration, and fetal hiccupping is differentiated from common fetal movements by some reasons (Table 1).

Table 1: Differentiation of fetal hiccupping from non-reactive FHR

	Resting fetal state	Non-reactive	Hiccupping
FHR acceleration	absent	absent	absent
FHR variability	present	present	present
Movement burst	absent	present	absent
Movement spike	absent	normal	very sharp, 2 sec intervals, continuous for 10 or more min, Sudden beginning & closure
Movement in real-time B-mode	absent	present	sudden extension every 2 sec

Results and Discussion

The continuous hiccupping movements were repeated with very sharp spikes in 2 seconds intervals, which was confirmed by the real-time ultrasound imaging to be sudden acute extension of fetal body, which regularly forms more sharp signals than common active fetal movements. Also, the hiccupping motion forms no movement burst, thus fetal hiccupping motion does not accompany FHR acceleration (Table 1).

In electronic simulation, short bursts of 10 Hz wave produced triangular wave passing through an integral circuits of which time constant was 7 sec (similar to fetal brain), that was the delay time of FHR to movement, and continuous 0.5 Hz wave of 20 min duration produced straight line without acceleration passing through the integral circuit. No production of FHR against fetal hiccupping movements was confirmed by the electronic simulation.

Thus, the differentiation of fetal hiccupping movements from the hypoxic loss of fetal acceleration was confirmed by its sudden repetition of very sharp movement signals characterized by regular 2 sec intervals, which was confirmed by increased recording chart speed and real-time B-mode imaging of fetal hiccupping motion, which was confirmed by electronic simulation (Table 1).

Differentiation of hiccupping from non-reactive FHR

Firstly, the actograms were different between non-reactive FHR and fetal hiccupping. There are multiple short fetal movement bursts in the non-reactive FHR without acceleration (Figure 2), while prolonged continuous 0.5 Hz spikes are recorded in the fetal hiccupping (Figure 3). In addition, resting fetal state is characterized by no acceleration without fetal movement burst. FHR variability is preserved in three situations, resting fetal state, non-reactive FHR and fetal hiccupping (Table 1). Usually some days or weeks after the loss of FHR acceleration, severe fetal asphyxia appeared, followed by fetal brain damage and cerebral palsy in fetal growth restriction [2], therefore, early caesarean delivery can be performed after the loss of acceleration and decreased FHR variability, or before 25 of novel hypoxia index value, while the delivery after the loss of variability, or the hypoxia index of 25 or more, will not guarantee to prevent cerebral palsy [3], despite it was possible to prevent fetal death.

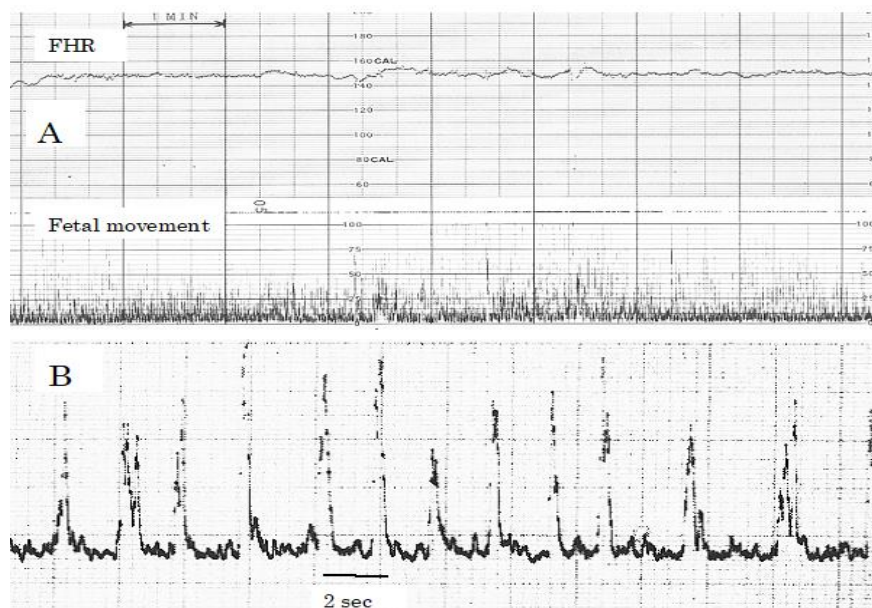


Figure 3: Fetal hiccupping movements **A)** It was recorded with common actocardiogram, where the movements repeated continuously 10 or more minutes, without forming movement burst. No FHR acceleration was recorded, despite there was no hypoxic sign, and neonatal state was favorable **B)** The same fetal movements as A by increased chart speed and amplitude. The spikes are very sharp, and its interval is repeatedly 2 seconds. Thus, it is the record of fetal hiccupping.

Conclusion

Fetal hiccapping motion should be differentiated from non-reactive FHR, because both of them accompany no FHR acceleration, while it is early sign of fetal hypoxia in non-reactive FHR. Fetal hiccapping is continuous spikes without forming the movement bursts in 10 or more minutes' continuation, while non-reactive movement forms triangular bursts. Hiccapping motion is regularly repeated very sharp spikes with mostly 2 seconds interval in high speed chart recording. Finally, the hiccapping is confirmed, if sudden fetal body extension is regularly repeated with 2 seconds interval in real-time B-mode ultrasound imaging.

Acknowledgement

It is authors pleasure to extend gratitudes to the members of Department of Obstetrics and Gynecology, Tottori University, and electronic simulation of Mr Nagasawa, TOITU.

References

1. Maeda K (2016) *Actocardiogram, Analysis of Fetal Motion and Heart Rate*. JP Medical Ltd, New Delhi, India.
2. Teshima N (1993) Non-reactive pattern diagnosed by ultrasonic Doppler fetal actocardiogram and outcome of the foetuses with non-reactive pattern. *Acta Obstet Gynecol Jpn* 45: 423-430.
3. Maeda K (2014) Modalities of fetal evaluation to detect fetal compromise prior to the development of significant neurological damage. *J Obstet Gynecol Res* 40: 2089-2094.